



Letter to the editor

aVR/V1 ST-segment elevation with diffuse depression in acute coronary syndrome with prior coronary artery bypass grafting

Elevación del ST en aVR/V1 con depresión difusa en el síndrome coronario agudo con puente aortocoronario previo

Armando Hong Ming Yee-Acendra ^{1,2,a,b}, Andrea Carolina Wilcox-Robles ^{3,4,a,c}

Received: March 24, 2026
Accepted: May 14, 2026
Online: May 30, 2026

To the Editor.

Authors' affiliation

- ¹ Pontificia Universidad Javeriana, Cali, Colombia.
 - ² Emergency and Trauma Medical Services Institute, Hospital Serena del Mar, Cartagena, Colombia.
 - ³ Universidad Libre, Barranquilla, Colombia.
 - ⁴ Inpatient Care Service, Hospital Serena del Mar, Cartagena, Colombia.
- ^a Physician.
^b Emergency Medicine Specialist.
^c General Practitioner.

Correspondence

Armando Hong Ming Yee-Acendra
Hospital Serena del Mar, Via Al Mar, Km 8, Cartagena, Bolívar, Colombia.
+57 3002868504

Email

amandoyee@javerianacali.edu.co

Funding

Self-funding.

Conflict of Interest

None.

Cite as:

Yee-Acendra AHM, Wilcox-Robles AC. aVR/V1 ST-segment elevation with diffuse depression in acute coronary syndrome with prior coronary artery bypass grafting. Arch Peru Cardiol Cir Cardiovasc. 2026;7(2):171-173. doi: 10.47487/apcyccv.v7i2.625.



This work is licensed under a Creative Commons Attribution 4.0 International License 4.0 Internacional

Diffuse ST-segment depression associated with ST-segment elevation in aVR (and occasionally in V1) constitutes an electrocardiographic pattern widely recognized in the context of acute coronary syndrome. Since its inclusion in the 2013 ST-elevation myocardial infarction management guidelines published by the American College of Cardiology Foundation and the American Heart Association, this pattern has been consistently linked to high-risk angiographic findings, including left main coronary artery obstruction, proximal involvement of the left anterior descending artery, or multivessel coronary disease.⁽¹⁾

This concept has been reinforced more recently by The Fourth Universal Definition of Myocardial Infarction (2018), published by the European Society of Cardiology in collaboration with the American College of Cardiology, the American Heart Association, and the World Heart Federation, which describes the presence of ST-segment depression ≥ 1 mm in multiple leads (at least six), in association with ST-segment elevation in aVR or V1, as a pattern suggestive of extensive myocardial ischemia, generally related to left main coronary artery disease or multivessel coronary disease.⁽²⁾

However, this electrocardiographic pattern has been previously described in the literature. Yamaji *et al.* were the first to systematically characterize its diagnostic and prognostic value through a retrospective study of electrocardiograms in patients with obstruction of the left main coronary artery, the left anterior descending artery, and the right coronary artery. In said study, ST-segment elevation in aVR was observed in 88% of patients with left main coronary artery obstruction, in 43% of those with involvement of the left anterior descending artery, and in 8% of cases with right coronary artery disease. Likewise, they demonstrated the ST-segment elevation ratio of elevation in aVR \geq V1 allows differentiation of left main coronary artery obstruction from other coronary locations. Additionally, by using a cutoff point of ST elevation ≥ 0.15 mV in aVR, they reported a predictive capacity for mortality with a sensitivity of 75% and a specificity of 75%, thus consolidating the diagnostic and prognostic value of this electrocardiographic pattern.⁽³⁾

In line with these findings, ST-segment elevation in aVR has been supported as an indicator of extensive coronary disease. Kosuge *et al.* showed that an ST elevation ≥ 0.05 mV in this lead is associated with left main involvement or three-vessel disease, demonstrating a sensitivity of 78% and a specificity of 86%, which reinforces its utility as an electrocardiographic marker of extensive myocardial ischemia.⁽⁴⁾

However, more contemporary studies have questioned the specificity of this pattern as a marker of acute coronary occlusion. In this sense, Harhash *et al.* found that ST elevation in aVR with diffuse ST depression was associated with acute thrombotic coronary occlusion in only 10% of cases, without evidence of involvement of the left main coronary artery or the left anterior descending artery. Although a significant proportion of patients presented severe coronary disease, in most cases, distal flow was preserved, suggesting a state of global subendocardial ischemia rather than acute epicardial occlusion. Nonetheless, this pattern was associated with high in-hospital mortality, reinforcing its prognostic rather than diagnostic value, which indicates that its interpretation must be integrated into the clinical context and not considered in isolation as an indication for emergent reperfusion, especially in complex scenarios such as patients with prior coronary artery bypass grafting, where its clinical significance may be even more challenging.⁽⁵⁾

This vision is supported by recent evidence that demystifies the exclusivity of this pattern as a pathognomonic sign of left main coronary artery lesions. Ahmed *et al.* (2023), in a prospective study that included 404 patients with acute coronary syndrome and aVR elevation associated with diffuse ST-segment depression, reported that the prevalence of left main coronary artery disease was only 29%, while the association with three-vessel disease was significantly more frequent (55%). The study underlines that the

magnitude of elevation in aVR (>1 mm) and the presence of comorbidities such as diabetes and hypertension substantially increase the diagnostic yield to identify severe coronary disease. Collectively, these data suggest that the pattern reflects extensive subendocardial ischemia secondary to a massive atherosclerotic burden and an exhausted coronary reserve, rather than a single focal thrombotic occlusion.⁽⁶⁾

Finally, the most robust evidence comes from the meta-analysis by Kazemi *et al.* (2022), who, after analyzing 45 studies and 52,175 patients, ratified the value of ST-segment elevation in aVR as a predictor of extensive coronary disease. The ORs for LMCA, 3VD, and the LMCA/3VD combination were 5.48 (95% CI: 3.88-7.76), 2.21 (95% CI: 1.78-3.27), and 6.21 (95% CI: 3.49-11.6), respectively. An elevation > 1 mm reached the highest sensitivity for LMCA (0.90; 95% CI: 0.82-0.98). Likewise, this pattern was associated with a risk three times higher of in-hospital death (OR 2.99; 95% CI: 1.90-4.72) and at 90 days (OR 3.09; 95% CI: 2.17-4.39), consolidating its prognostic impact in acute coronary syndrome.⁽⁷⁾

Based on the above, we can conclude that the validity of this pattern is clear in native coronary anatomy; however, the same does not occur in patients with a history of myocardial revascularization surgery, in whom the presence of aortocoronary bypasses can modify the dynamics of subendocardial ischemia, hindering the identification of the culprit artery. Therefore, the electrocardiographic-angiographic correlations that explain generalized ST-segment depressions in this group of patients are not well established.

Faced with this information gap, we present the case of a 61-year-old male patient with a history of arterial hypertension, type II diabetes mellitus, stage V chronic kidney disease on peritoneal dialysis, and ischemic heart disease. He had previously undergone myocardial revascularization with a triple coronary bypass without extracorporeal circulation (internal mammary artery to the descending anterior and saphenous vein in a sequential graft to the marginal and descending posterior) who consulted the emergency department for cardiac pain of ischemic origin, with two positive troponin determinations. The electrocardiogram evidenced ST-segment elevation in aVR and V1, with ST-segment depression in V3, V4, V5, V6, DI, DII, and aVL (**Figure 1**). Coronary angiography was performed, revealing patency of the mammary graft to the descending anterior and the absence of the venous graft, suggestive of 100% occlusion. In the native circulation, total occlusion (100%) of the mid-third of the descending anterior was documented, with 70% proximal and distal stenosis of the circumflex and a 90% ostial lesion in the first marginal, along with chronic total occlusion (100%) of the mid-third right coronary artery with collateral filling, configuring multivessel disease. The patient did not accept additional therapeutic procedures and requested voluntary discharge.

In contrast to the above, we present the second case corresponding to the only report described in the literature of this electrocardiographic pattern in this type of patient, published by Kashou *et al.* in 2019. It concerns a 69-year-old male patient with a history of mechanical aortic valve replacement for a bicuspid valve and myocardial revascularization with an internal mammary artery graft to the

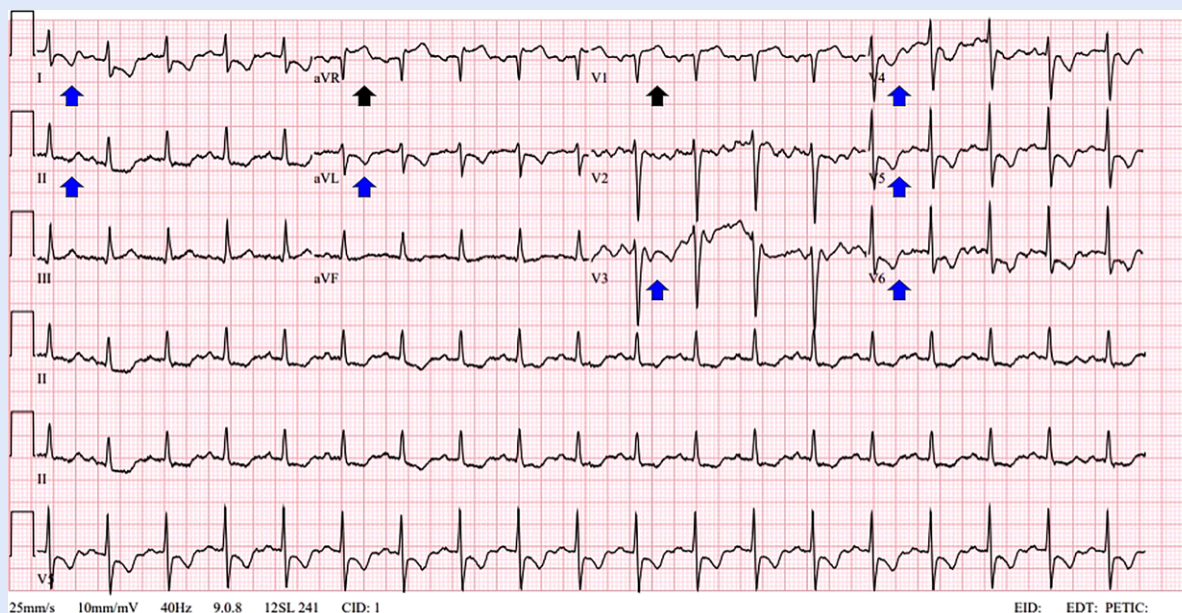


Figure 1. ST-segment elevation in aVR and V1 with diffuse ST-segment depression. A 12-lead electrocardiogram shows ST-segment elevation in aVR and V1 (black arrows), associated with diffuse ST-segment depression in multiple leads, including I, II, aVL, V3, V4, V5, and V6 (blue arrows). These findings are suggestive of left main coronary artery disease or multivessel disease.

descending anterior and a saphenous vein to the circumflex, in addition to previous percutaneous coronary intervention with stents in the circumflex and marginal branches. He consulted for cardiac chest pain of ischemic characteristics, associated with diaphoresis and dyspnea. He presented with high-sensitivity troponin T elevation with a subsequent significant peak. The electrocardiogram showed ST elevation in aVR and V1, with diffuse ST depression in the precordial (V2–V6), lateral (DI and aVL), and inferior (DII, DIII, and aVF) leads. Coronary angiography evidenced a 90% occlusive lesion in the distal segment of the left main coronary artery and 90% critical stenosis in the ostium of the right coronary artery, with the patency of the mammary graft to the descending anterior. Successful percutaneous coronary intervention was performed with the implantation of drug-eluting stents in both territories.⁽⁸⁾

Altogether, both cases evidence that the ST-elevation pattern in aVR/V1 with diffuse ST depression remains a marker of extensive subendocardial ischemia in patients with a history

of myocardial revascularization, although with less anatomical specificity. Unlike native coronary circulation, where it has been related to involvement of the left main coronary artery or multivessel disease, the presence of patent or occluded grafts can modify the distribution of coronary flow and, therefore, the electrocardiographic expression of ischemia. Both our case and the one reported by Kashou *et al.* show severe coronary disease without a consistent correlation with a single culprit vessel, which suggests a mechanism of global ischemia rather than focal occlusion. In conclusion, in revascularized patients, this pattern must be interpreted in a contextualized manner, integrating clinical and angiographic findings and avoiding simplistic anatomical inferences.

Author Contributions

AHMYA: conceptualization, formal analysis, writing – original draft, writing – review and editing. **ACWR:** formal analysis, writing – original draft.

References

- O’Gara PT, Kushner FG, Ascheim DD, Casey DE Jr, Chung MK, de Lemos JA, *et al.* 2013 ACCF/AHA Guideline for the Management of ST-Elevation Myocardial Infarction: A Report of the American College of Cardiology Foundation/American Heart Association Task Force on Practice Guidelines. *Circulation*. 2013;127(4):e362-425. doi: 10.1161/CIR.0b013e3182742cf6.
- Thygesen K, Alpert JS, Jaffe AS, Chaitman BR, Bax JJ, Morrow DA, *et al.* Fourth Universal Definition of Myocardial Infarction (2018). *Circulation*. 2018;138(20):e618-e651. doi: 10.1161/CIR.0000000000000617.
- Yamaji H, Iwasaki K, Kusachi S, Murakami T, Hiram R, Hamamoto H, *et al.* Prediction of acute left main coronary artery obstruction by 12-lead electrocardiography. ST segment elevation in lead aVR with less ST segment elevation in lead V1. *J Am Coll Cardiol*. 2001;38(5):1348-54. doi: 10.1016/s0735-1097(01)01563-7.
- Kosuge M, Kimura K, Ishikawa T, Ebina T, Shimizu T, Hibi K, *et al.* Predictors of left main or three-vessel disease in patients who have acute coronary syndromes with non-ST-segment elevation. *Am J Cardiol*. 2005;95(11):1366-9. doi: 10.1016/j.amjcard.2005.01.085.
- Harhash AA, Huang JJ, Reddy S, Natarajan B, Balakrishnan M, Shetty R, *et al.* aVR ST Segment Elevation: Acute STEMI or Not? Incidence of an Acute Coronary Occlusion. *Am J Med*. 2019;132(5):622-630. doi: 10.1016/j.amjmed.2018.12.021.
- Ahmed S, Khatti S, Shah GA, Khan N, Rai L, Khan MZ, *et al.* Diffuse ST Depression With ST Elevation aVR In Acute Coronary Syndrome And Its Association With Significant Left Main Or Three Vessel Coronary Artery Disease And Its Confounders. *J Ayub Med Coll Abbottabad*. 2023;35(1):105-109. doi: 10.55519/JAMC-01-10590.
- Kazemi E, Mansoursamaei A, Bijan M, Hosseinzadeh A, Sheibani H. The prognostic effect of ST-elevation in lead aVR on coronary artery disease, and outcome in acute coronary syndrome patients: a systematic review and meta-analysis. *Eur J Med Res*. 2022;27(1):302. doi: 10.1186/s40001-022-00931-5.
- Kashou AH, May AM, DeSimone CV, Deshmukh AJ, Asirvatham SJ, Noseworthy PA. Diffuse ST-segment depression despite prior coronary bypass grafting: An electrocardiographic-angiographic correlation. *J Electrocardiol*. 2019;55:28-31. doi: 10.1016/j.jelectrocard.2019.04.014.