



Case report

Neo-Aortoiliac reconstruction of complicated aneurysms: First case report in a Peruvian hospital

Helen Sofía Choquehuanca-Bedoya ^{1,2,a}, Jarol Isaac Núñez-Barrientos ^{1,b}, Mónica Danae Pérez-Cuello ^{1,2,a}, Martín Augusto Gil-Cusirramos ^{1,b}, Neyel Abner Cáceres-Cancho ^{1,b}, Daniel Silva-Naupari^{1,b}

Received: February 09, 2026
Accepted: April 23, 2026.
Online:

Authors' affiliation

- ¹ Vascular Surgery Unit, Hospital Nacional Guillermo Almenara, Lima, Peru.
² Thoracic and Cardiovascular Surgery, Universidad Nacional Mayor de San Marcos, Lima, Peru.
^a Thoracic and Cardiovascular Surgery Fellow.
^b Thoracic and Cardiovascular Surgeon.

Correspondence

Helen Sofía Choquehuanca-Bedoya. Vascular Surgery, Hospital Nacional Guillermo Almenara. Av. Grau 800, La Victoria, Lima, 15018, Peru.

Email

helen.choquehuanca@unmsm.edu.pe

Funding

None.

Conflicts of interest

None.

Cite as

Choquehuanca-Bedoya HS, Núñez-Barrientos JI, Pérez-Cuello MD, Gil-Cusirramos MA, Cáceres-Cancho NA, Silva-Naupari D. Neo-Aortoiliac reconstruction of complicated aneurysms: First case report in a Peruvian hospital. Arch Peru Cardiol Cir Cardiovasc. 2026;7(2). doi: 10.47487/apcyccv.v7i2.608.



This work is licensed under a Creative Commons Attribution 4.0 International License

ABSTRACT

Mycotic aneurysms are rare vascular pathologies requiring tailored surgical approaches in septic and anatomically complex settings. We present the case of a 68-year-old male with diabetes mellitus and tobacco use, admitted with abdominal sepsis and purulent perianal discharge. Imaging revealed a ruptured 90 mm infrarenal abdominal aortic aneurysm with features suggestive of an aortomesenteric fistula. Due to the high risk of prosthetic graft infection, aortic reconstruction with an autologous femoral vein was selected. After preoperative venous mapping, a bifurcated graft was constructed using a reversed femoral vein following the Neo-aortoiliac system principles and the Myller cuff technique. During laparotomy, the contained ruptured aneurysm with multiple adhesions was confirmed, and the autologous graft was interposed proximally at the aorta and distally at the iliac arteries. This case highlights the feasibility of autologous vein grafting in complex infected aortic reconstruction within a septic setting.

Keywords: Aorta; Mycotic Aneurysm; Femoral Vein; Vascular Surgical Procedures (Source: NLM-MeSH).

RESUMEN

Reconstrucción neo-aortoiliaca de aneurismas complicados: primer reporte de caso en un hospital peruano

Los aneurismas micóticos son patologías vasculares poco frecuentes que requieren enfoques quirúrgicos personalizados en contextos sépticos y anatómicamente complejos. Presentamos el caso de un varón de 68 años con diabetes *mellitus* y hábito tabáquico, ingresado por sepsis abdominal y secreción purulenta perianal. Las imágenes revelaron un aneurisma de la aorta abdominal infrarrenal de 90 mm con ruptura, con características sugestivas de fístula aortomesentérica. Debido al alto riesgo de infección del injerto protésico, se optó por la reconstrucción aórtica mediante vena femoral autóloga. Tras el mapeo venoso preoperatorio, se construyó un injerto bifurcado utilizando la vena femoral invertida, siguiendo los principios del sistema neo-aortoiliaco y la técnica del *cuff* venoso de Myller. Durante la laparotomía, se confirmó el aneurisma roto contenido con múltiples adherencias, y el injerto autólogo se intercaló proximalmente en la aorta y distalmente en las arterias ilíacas. Este caso resalta la factibilidad del uso de injertos venosos autólogos en reconstrucciones aórticas complejas infectadas dentro de un contexto séptico.

Palabras clave: Aorta; Aneurisma Micótico; Vena Femoral; Procedimientos Quirúrgicos Vasculares (Fuente: DeCS-BIREME).

Introduction

The term *mycotic aneurysm* was originally coined to describe infected aortic aneurysms, first reported by Osler in 1885.⁽¹⁻³⁾ Mycotic aneurysms are associated with high morbidity and mortality, and their pathophysiology remains incompletely understood. Bacterial colonization of the endothelium, typically occurring in previously damaged segments, triggers an intense inflammatory response that weakens the vascular wall, promoting dilation and eventual rupture.^(4,5) In this context, an aortoenteric fistula may develop due to erosion into the gastrointestinal tract. Although extremely rare, this complication is potentially fatal, with mortality approaching 100% without treatment and remaining high even after surgical intervention.⁽⁶⁻⁸⁾ In 1993, Clagett described the use of femoral veins as an alternative conduit for aortic grafting, a technique later termed the neo-aortoiliac system (NAIS). This approach has demonstrated utility in the management of primary aortic infections, aortoenteric fistulas, and infections involving synthetic grafts.^(4,6,7)

We report a case of aortic reconstruction using a femoral vein allograft (FV) in a patient presenting with abdominal sepsis associated with an aortic aneurysm complicated by an aortoenteric fistula.

Case report

A 68-year-old male with a history of diabetes mellitus and chronic tobacco use presented to the emergency department with a 14-day history of fever and purulent perianal discharge. Microbiological cultures isolated extended-spectrum β -lactamase (ESBL)-producing *Escherichia coli*. During hospitalization, the patient developed severe epigastric pain, followed by episodes of coffee-ground vomiting (~900 mL), a decline in hemoglobin from 10.2 g/dL to 6.9 g/dL, and elevated liver transaminases. Computed tomography (CT) revealed a 90 mm infrarenal abdominal aortic aneurysm with a non-dilated proximal neck

(26 mm). The common iliac arteries measured 11 mm on the right and 10 mm on the left, without significant stenosis. Active contrast extravasation and periaortic gas were noted, findings highly suggestive of an aortoenteric fistula. (**Figure 1**)

Emergency surgery was planned. The surgical team carefully considered graft selection for aortic replacement. Given the coexistence of a mycotic aneurysm and an aortoenteric fistula, the operative field was deemed highly contaminated, precluding the use of prosthetic grafts. Cryopreserved allografts were not available at our institution, and extra-anatomic bypass was excluded due to its inferior long-term patency and the presence of active infection. Reconstruction using the NAIS with autologous femoral vein was considered the most appropriate strategy, providing a biological conduit with a lower risk of reinfection and favorable long-term patency.

Preoperative venous mapping using duplex ultrasound showed a right femoral vein measuring 10 mm proximally and 8 mm distally, with an estimated usable length of 32 cm. The left femoral vein measured 8 mm proximally and 7.5 mm distally. Both veins were patent, compressible, and suitable for autologous graft harvesting.

In the first stage, the right femoral vein was harvested using the technique described by Eidt, distal to the origin of the great saphenous vein.⁽⁵⁾ Through a longitudinal incision in the right thigh, venous tributaries were ligated, and the graft was flushed with a heparinized solution. The graft was reversed to prevent valvular obstruction without requiring valvulotomy and was divided into three segments for branch construction and proximal reconstruction. A Miller venous cuff was used, consisting of an interposed venous segment fashioned from the graft to increase the anastomotic diameter and reduce size mismatch with the recipient artery. A truncated cone was created from a trapezoid-shaped venous segment and sutured in a collar configuration to the preformed pantaloon graft.⁽⁹⁾ The graft measured 12 cm, with a 25 mm proximal diameter and 8–9 mm distal branches. (**Figure 2**) Simultaneously, the right femoral artery was dissected to allow the insertion of a suprarenal intra-aortic occlusion balloon for hemorrhage control. A 0.035-inch hydrophilic

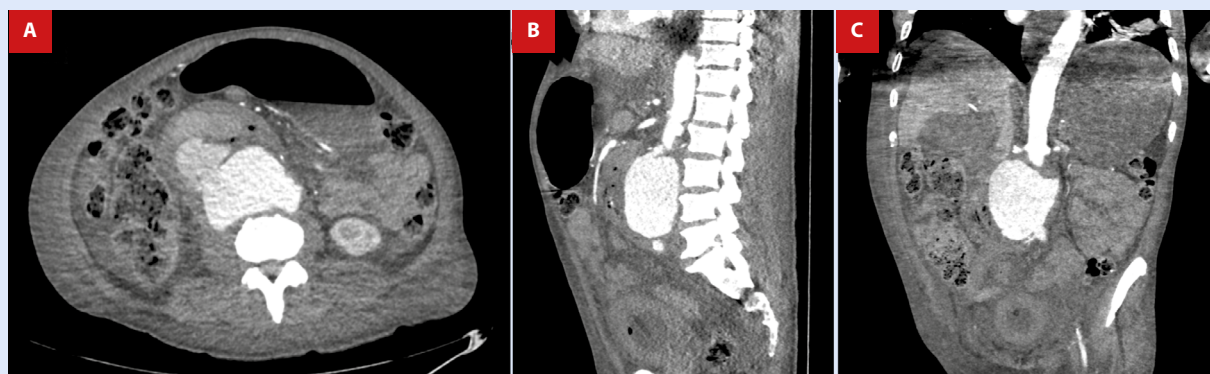
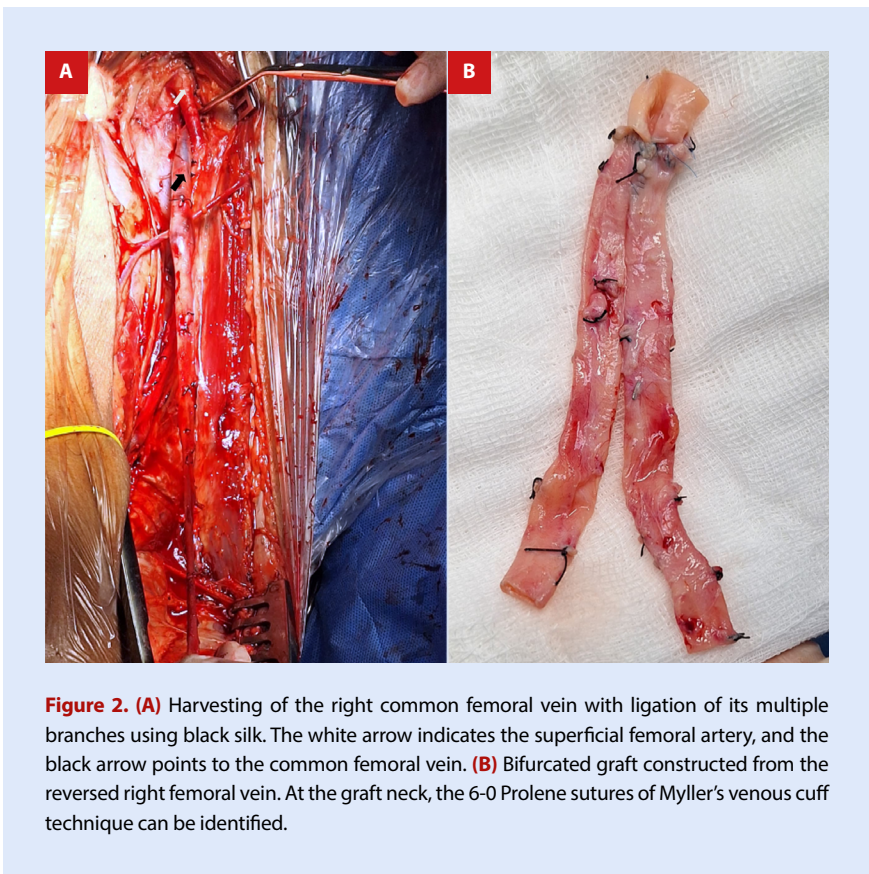


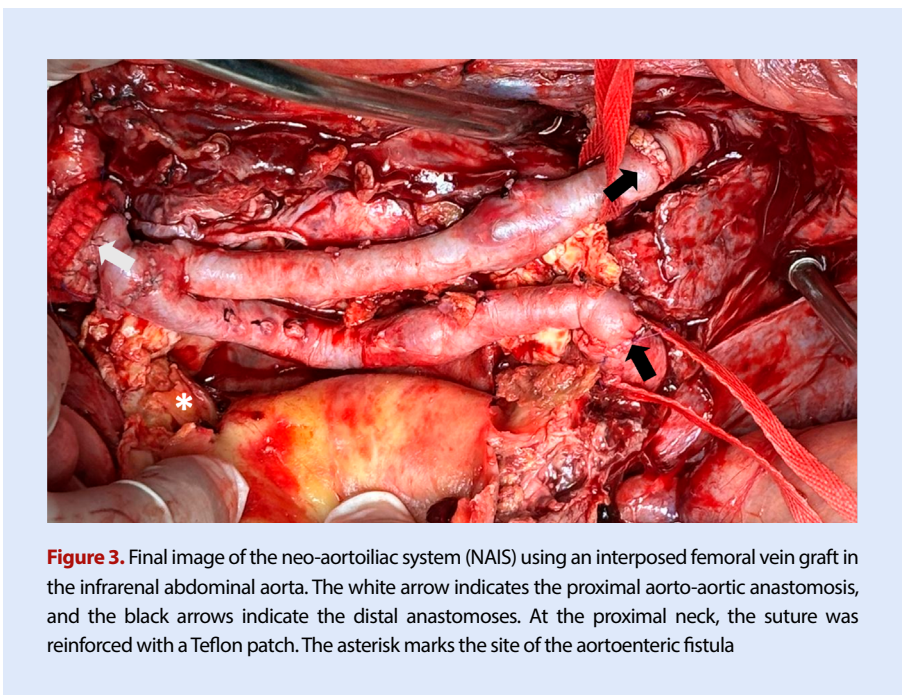
Figure 1. CT angiography demonstrates a contained rupture of an infrarenal abdominal aortic aneurysm measuring 90 × 92 × 81 mm, with an intramural thrombus of approximately 21 mm, active contrast extravasation, and periaortic gas. (A) Axial views, (B) sagittal views, and (C) coronal views.



guidewire was advanced under fluoroscopic guidance, followed by the deployment of a compliant occlusion balloon (Reliant™).

In the second stage, a laparotomy was performed, revealing turbid peritoneal fluid and dense inflammatory tissue encasing the abdominal aortic aneurysm, with extensive retroperitoneal adhesions. A contained rupture was identified on the anterior wall of the abdominal aorta adjacent to the duodenum, inferior vena

cava, and left renal vein. Ligation of the left renal vein was required due to dense adhesions, improving exposure of the aneurysm neck. Proximal anastomosis was performed using continuous 5-0 polypropylene suture with Teflon felt reinforcement in a “wrap-around” configuration at the native aortic neck. Distal anastomoses were completed using continuous 6-0 polypropylene suture (Figure 3). Intraoperatively, communication between the



abdominal aorta and the adjacent duodenum was identified. Following resection of the affected aortic segment and vascular control, the duodenal defect was managed with primary closure and extensive abdominal lavage. After the completion of vascular reconstruction and confirmation of hemostasis, the abdominal wall was closed primarily. The patient was transferred to the intensive care unit for postoperative monitoring.

During the first 48 postoperative hours, the patient showed slow but favorable progression, without signs of bleeding. Intraoperative cultures were negative for common pathogens, showing a predominance of mononuclear cells. However, the patient subsequently developed acute renal failure requiring renal replacement therapy. Isolation of *Candida tropicalis* prompted consideration of antifungal therapy, given the potential nephrotoxicity. Despite intensive supportive care, the patient progressed to multiorgan failure secondary to septic shock and ultimately died.

Discussion

Mycotic aneurysms represent approximately 1% of all aortic aneurysms.⁽²⁾ Although uncommon, they represent a potentially life-threatening condition, particularly when associated with rupture or aortoenteric fistula. In the absence of treatment, mortality approaches 100%; even with surgical management, perioperative mortality ranges from 40% to 60% in ruptured cases and 30% to 70% in primary aortoenteric fistulas.^(4,7,8)

Despite their rarity, they pose a major surgical challenge. The infrarenal aorta is most frequently affected, often due to contiguous spread from adjacent abdominal infections. *Staphylococcus* species are the most frequently identified pathogens; however, gram-negative organisms are associated with more aggressive disease, an increased risk of rupture, and higher mortality.^(2,4) In the present case, *Escherichia coli* was isolated preoperatively, suggesting an enteric source of infection. The identification of *Candida tropicalis* is uncommon but clinically significant, given the higher morbidity and mortality associated with fungal aortic infections, and may reflect intestinal translocation and enteric contamination of the operative field.

Computed tomography angiography is the imaging modality of choice for diagnosis.⁽⁴⁾ Typical radiologic findings include aortic wall irregularity, adjacent soft tissue masses, periaortic edema, and the presence of gas within the periaortic space.⁽¹⁾ In our patient, peri-aortic gas and contrast extravasation into adjacent bowel loops were highly suggestive of a mycotic aneurysm.

Management requires prolonged broad-spectrum antibiotic therapy—occasionally lifelong^(4,9)—in conjunction with radical surgical intervention, including debridement of infected tissue, excision of the affected aortic segment, and intraoperative culture sampling to guide targeted antimicrobial therapy.^(5,6)

The most challenging aspect of management lies in surgical planning and optimal graft selection. The presence of active infection and enteric contamination significantly increases the risk of graft-related complications, particularly reinfection. Prosthetic grafts used for in situ reconstruction or extra-anatomic bypass are associated with reinfection rates of 10% to 20% in infected fields. Although antibiotic-bonded grafts (e.g., rifampicin-soaked) may reduce this risk, their efficacy is limited in cases of severe contamination and aortoenteric fistula.^(4,7,8)

Autologous reconstruction using the NAIS with the femoral vein has emerged as a durable alternative. Contemporary series report long-term patency rates exceeding 80% to 90% and low reinfection rates (5% to 6%), reflecting greater resistance to bacterial colonization compared with prosthetic materials. In addition, outcomes comparable to cryopreserved allografts have been described, particularly in heavily contaminated fields.^(8,10,11)

In the present case, the coexistence of a mycotic aneurysm and an aortoenteric fistula created a highly contaminated operative environment, favoring the use of an autologous conduit. NAIS reconstruction provided a biologically sound solution with reduced reinfection risk and favorable durability.

In low-resource settings, limited access to cryopreserved grafts further supports the use of femoral vein reconstruction as a cost-effective and reproducible strategy. However, evidence remains limited to small retrospective series, and the high early mortality associated with this condition restricts long-term outcome data. Multicenter studies are needed to standardize management and improve the quality of evidence. The establishment of specialized aortic programs may further contribute to the development of standardized protocols and the generation of more robust data in this patient population.

Authors contribution

HSCB: Conceptualization, Writing – review & editing. **JINB:** Conceptualization, Investigation. **MDPC:** Data curation, Writing – review & editing. **MAGC:** Data curation, Investigation. **NACC:** Conceptualization. **DSN:** Writing – review & editing.

Ethical considerations

Written informed consent was obtained from the patient's next of kin prior to surgery and subsequently for publication of this case report.

References

- Somers T, Nies HMJM, Kouijzer IJE, Lee PY, Morshuis WJ, Geuzebroek GSC. Mycotic aortic aneurysms: characteristic macroscopic findings in a case series. *Scand Cardiovasc J.* 2024;58(1):234-1696. doi: 10.1080/14017431.2024.2341696.
- Perez Burkhardt JL. Aneurismas micóticos: particularidades diagnósticas y de tratamiento. *Angiología.* 2015;68(1):46-54. doi: 10.1016/j.angio.2015.06.003.
- Ghaly P, Di Mascio D, Vicaretti M. Infrarenal aortic reconstruction using autologous femoral vein for a mycotic aneurysm caused by *Streptococcus equi*. *J Surg Case Rep.* 2021;2021(9):rjab388. doi: 10.1093/jscr/rjab388.
- Sörelius K, Budtz-Lilly J, Mani K, Wanhainen A. Systematic Review of the Management of Mycotic Aortic Aneurysms. *Eur J Vasc Endovasc Surg.* 2019;58(3):426-435. doi: 10.1016/j.ejvs.2019.05.004.

5. Eidt JF, Gucwa AL, Ali A. How I do it: The neoaortoiliac system for treatment of aortoduodenal fistula after endovascular aortic repair. *J Vasc Surg Cases Innov Tech.* 2022;8(4):830-839. doi: 10.1016/j.jvscit.2022.11.001.
6. Shao CC, McFarland GE, Beck AW. Emergent repair of infected aortic aneurysm with contained rupture using a femoral vein neoaortoiliac system. *J Vasc Surg Cases Innov Tech.* 2021;7(3):502-505. doi: 10.1016/j.jvscit.2021.06.003.
7. Chakfé N, Diener H, Lejay A, Assadian O, Berard X, Caillon J, *et al.* Editor's Choice - European Society for Vascular Surgery (ESVS) 2020 Clinical Practice Guidelines on the Management of Vascular Graft and Endograft Infections. *Eur J Vasc Endovasc Surg.* 2020;59(3):339-384. doi: 10.1016/j.ejvs.2019.10.016.
8. Wu JW, Zhang Y, Chen SR, Seeruttun SR, Ke CL, Hu WX, *et al.* Aortoenteric fistula: clinical features, diagnostic challenges, and surgical outcomes - a retrospective analysis of 10 cases. *BMC Gastroenterol.* 2025;26(1):38. doi: 10.1186/s12876-025-04539-x.
9. Ghista DN, Kabinejadian F. Coronary artery bypass grafting hemodynamics and anastomosis design: a biomedical engineering review. *Biomed Eng Online.* 2013;12:129. doi: 10.1186/1475-925X-12-129.
10. Krzyzaniak H, Vergouwen M, Xuan-Zeng R, Rockley M, Rommens K, Moore RD. Long-term outcomes of neoaortoiliac system for treatment of aortic graft infection. *JVS Vasc Insights.* 2025;3:100194. doi: 10.1016/j.jvsvi.2025.100194.
11. Lyons OT, Patel AS, Saha P, Clough RE, Price N, Taylor PR. A 14-year experience with aortic endograft infection: management and results. *Eur J Vasc Endovasc Surg.* 2013;46(3):306-13. doi: 10.1016/j.ejvs.2013.04.021.